



Clinical Kidney Journal, 2016, 1–3

doi: 10.1093/ckj/sfw085

Exceptional Case

EXCEPTIONAL CASE

Primary sclerosing cholangitis: a new cause of distal renal tubular acidosis

Valentin Goutaudier¹, Ilan Szwarc¹, Jean-Emmanuel Serre¹,
Georges-Philippe Pageaux², Àngel Argilés^{3,4} and Jean Ribstein⁵

¹Department of Nephrology, Dialysis and Transplantation, Hôpital Lapeyronie, University of Montpellier Medical School, Montpellier, France, ²Department of Hepato-Gastro-Enterology and Liver Transplantation, Hôpital Saint Eloi, University of Montpellier Medical School, Montpellier, France, ³SAS RD – Nephrology, Montpellier, France, ⁴Department of Nephrology and Dialysis Saint-Guilhem, Sète, France and ⁵Department of Hypertension and Internal Medicine, Hôpital Lapeyronie, University of Montpellier Medical School, Montpellier, France

Correspondence and offprint request to: Jean Ribstein; E-mail: j-ribstein@chu-montpellier.fr

Abstract

We describe the first case of distal renal tubular acidosis (dRTA) associated with primary sclerosing cholangitis. A 26-year-old Lao-Thai male patient presented with severe jaundice, metabolic acidosis and hypokalaemia. He was diagnosed of dRTA. Liver transplantation resulted in correction of electrolyte disturbances and hyperbilirubinaemia. A fludrocortisone-furosemide test revealed normal urinary acidification, demonstrating no residual dRTA. This observation suggests that dRTA may be an early manifestation of bilirubin-associated nephropathy or the consequence of an immune mechanism.

Key words: distal renal tubular acidosis, liver transplantation, primary sclerosing cholangitis

Background

Renal tubular acidosis is considered when a relatively normal glomerular filtration rate is associated with metabolic acidosis, hyperchloremia and a normal plasma anion gap [1]. Distal renal tubular acidosis (dRTA) is characterized by an impairment of net acid secretion by the distal tubule and may be associated with hypokalaemia (type I) or hyperkalemia (type IV). Nephrocalcinosis, recurrent renal calculi and reduced bone mineral density are often present. It can be either inherited, idiopathic or acquired secondary to a variety of conditions [1, 2]. For example, autosomal dominant or recessive mutations in the anion exchanger 1 (AE1) gene encoding the erythroid and kidney anion exchanger 1 (chloride-bicarbonate) may result in dRTA with ovalocytosis or spherocytosis in patients from Southeast Asia [3]. The most

common causes of secondary dRTA are autoimmune disorders such as systemic lupus erythematosus [4], Sjögren's syndrome [5] and primary biliary cirrhosis [6]. Of note, primary sclerosing cholangitis (PSC) is often compared to primary biliary cirrhosis, but no PSC-associated dRTA has been previously reported.

We report a case of type I dRTA occurring during the course of PSC that was corrected by a successful liver transplantation.

Case report

A 26-year-old Lao-Thai male patient with uneventful previous medical records was diagnosed as severe (Child score B7, Model for End-Stage Liver Disease (MELD) score 24) hepatic cirrhosis secondary to PSC in August 2012. Biliary magnetic resonance imaging revealed an irregular aspect of intrahepatic bile ducts with

Received: September 29, 2015. Accepted: June 17, 2016

© The Author 2016. Published by Oxford University Press on behalf of ERA-EDTA.

This is an Open Access article distributed under the terms of the Creative Commons Attribution Non-Commercial License (<http://creativecommons.org/licenses/by-nc/4.0/>), which permits non-commercial re-use, distribution, and reproduction in any medium, provided the original work is properly cited. For commercial re-use, please contact journals.permissions@oup.com

alternance of stenosis and dilatation (similar to a 'stack of plates'). Liver biopsy showed mild inflammation in the portal spaces and major cholestasis in hepatocytes and bile ducts, with no sign of suppurated cholangitis, obliteration, or cholangiocarcinoma. Anti-mitochondrial, anti-smooth muscle, anti-liver cytosol, anti-endoplasmic reticulum, anti-neutrophil cytoplasmic and anti-nuclear antibodies were negative. No inflammatory bowel disease was detected.

During the following months he developed a marked hypokalaemia resistant to potassium replacement therapy, followed by metabolic acidosis. At referral to the renal department he had severe jaundice, generalized muscle weakness and bone pain. Body mass index was 22.3 kg/m² and blood pressure was 110/70 mmHg with no sign of volume depletion. He was treated with esomeprazole, cholestyramine and ursodeoxycholic acid.

Metabolic acidosis [arterial pH 7.34, partial pressure of carbon dioxide (pCO₂) 27 mmHg, bicarbonatemia 15 mmol/L] was associated with hyperchloremia (117 mmol/L), a normal plasma anion gap [17.6 mmol/L (normal 16 ± 4 mmol/L); 18.1 mmol/L after correction for albumin, albuminemia 38 g/L], a positive urinary anion gap (7.6 mmol/L) and an inappropriate urinary pH of 6. Hypokalaemia (2.7 mmol/L) was associated with a normal electrocardiogram, inadapted renal potassium loss (urinary potassium excretion 88 mmol/day), normal blood magnesium (1.0 mmol/L), increased plasma renin activity (188 pg/mL) and normal aldosterone level (13 ng/dL). Serum creatinine was 80 µmol/L (normal range 70–110 µmol/L). Urinalysis showed urinary sodium at 39 mmol/L (fractional excretion of sodium 1.3%), moderate proteinuria (protein:creatinine ratio 650 mg/g, urinary albumin:creatinine ratio 50 mg/g), calcium:creatinine ratio of 10.7 mmol/g and the absence of glycosuria, aminoaciduria, inappropriate phosphaturia, leukocyturia and haematuria. Urinary NH₄ and citrate were not measured. Liver investigations showed severe cholestasis with a total bilirubin value of

831 µmol/L (normal <21 µmol/L), mainly conjugated [762 µmol/L (normal <3.4 µmol/L)]. Blood cell count was indicative of regenerative normocytic anaemia (haemoglobin 9.5 g/dL, mean cell volume 82 fL, reticulocytes 119.000/mm³), thrombocytosis (456.000/mm³) and leukocytosis (11.670/mm³). Heterozygous beta thalassemia [haemoglobin (Hb) A 93.0%, Hb A2 6.0%, Hb F <1%] was demonstrated by electrophoresis. Testing for SCL4A1 gene mutation, commonly associated with dRTA in the Southeast Asian population [3], was negative. Simple renal cortical cysts but no calcinosis or lithiasis were noticed on computed tomography. Osteodensitometry was normal.

During the alkali infusion test, the urine to blood pCO₂ gradient did not rise normally (i.e. >30 mmHg when bicarbonaturia approaches 80 mEq/L), indicative of a low rate of H⁺ secretion [7, 8]. In the present case, the maximal urine to blood pCO₂ gradient at bicarbonaturia of 80 mEq/L was 1.2 mmHg while urinary pH and pCO₂ were 7.1 and 33 mmHg, respectively.

The opportunity of liver transplantation was taken and the patient was transplanted in July 2013, before a furosemide-fludrocortisone test and a kidney biopsy were performed. Native liver biopsy confirmed the diagnosis of PSC. Induction immunosuppressive therapy consisted of basiliximab, methylprednisolone, tacrolimus and mycophenolate mofetil. Maintenance immunosuppression included prednisolone, tacrolimus and mycophenolate mofetil. As shown in Figure 1, hypokalaemia and acidosis disappeared upon correction of bilirubinemia. Renal function was normal during the initial postoperative period. A mild and stable increase in serum creatinine (130 µmol/L) without proteinuria (proteinuria:creatininuria ratio 50 mg/g) occurred about 1 month later and was attributed to calcineurin inhibitor toxicity. A fludrocortisone-furosemide test was normal 6 months after liver transplantation with normal urinary acidification and urinary pH of 4.77.

DISCUSSION

To our knowledge, this is the first described case of type I dRTA associated with PSC. Interestingly, renal tubular dysfunction was corrected by liver transplantation.

Since the patient originated from Laos, an inherited mechanism—namely SLC4A1 gene mutation—was suspected and eliminated. This gene encodes for anion exchanger 1 (AE1), a bicarbonate/chloride transporter localized in both red cell membrane and basolateral membrane of the collecting tubule alpha-intercalated cell. Its mutations are common in Southeast Asia and result in dRTA and ovalocytosis, which can occur in adulthood [3]. Two other mutations in genes encoding for the α4 (ATP6V0A4) and β1 (ATP6V1B1) subunits of the V-ATPase of the alpha-intercalated cells of the collecting duct can also cause hereditary dRTA. We did not perform gene sequencing for these genes because the onset of the disease occurs in childhood (ATP6V0A4) and is associated with sensorineural deafness (ATP6V1B1). Moreover, altered urinary acidification could not be attributed to impaired distal sodium delivery [9], as fractional excretion of sodium was not low.

Immune disorders are frequent causes of acquired dRTA. Of note, the ion disturbances of dRTA were corrected in this patient a few weeks after liver transplantation with immunosuppressive therapy. Sjögren's syndrome is associated with dRTA, and several reports suggest that autoantibodies against carbonic anhydrase II enzyme [10] or vacuolar H⁺-ATPase pump in the collecting duct [11] are involved in the pathogenesis of dRTA. In a recent unusual case of multiorgan autoimmunity, circulating autoantibodies directed against intercalated cells were apparently

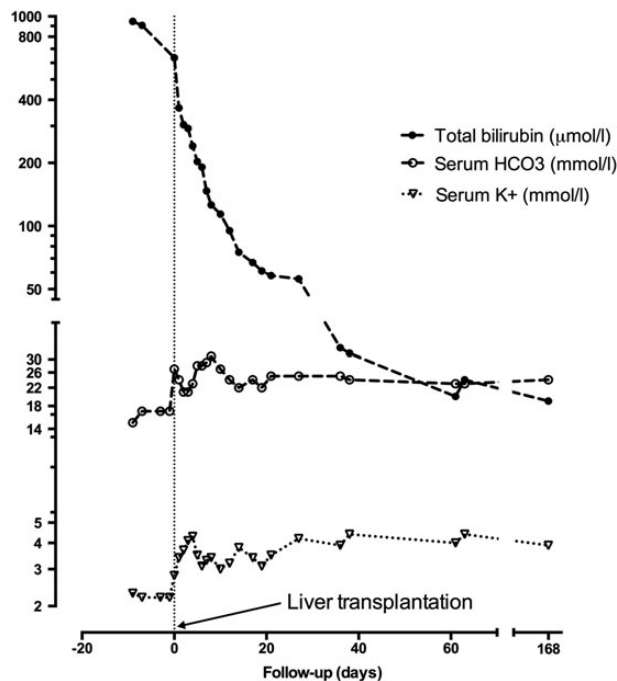


Fig. 1. Improvement in distal renal tubular acidosis-associated disorders (metabolic acidosis and hypokalaemia) was concomitant with the decrease in total bilirubin following liver transplantation.

involved in the pathogenesis of dRTA [12]. Primary biliary cirrhosis is an autoimmune liver disease associated with dRTA and tubulointerstitial nephritis that is alleviated by steroid therapy [6]. However, PSC is not considered an autoimmune disease, but rather an inflammatory condition. Male predominance, lack of a defined pathogenic autoantigen and the potential role of the innate immune system suggest that it may be due to dysregulation of immunity [13].

Although frequently overlooked, bilirubin is a recognized renal toxin, and in the present case bilirubin levels were normalized concomitant to the correction of dRTA. Rafat *et al.* [14] recently reported the case of an adult kidney recipient who developed a malignant cholangiocarcinoma 4 years after transplantation and progressively lost transplant function in parallel with a continuous increase in bilirubinemia. Kidney biopsy showed bile thrombi in dilated tubules and bile granules in the cytoplasm of tubular epithelial cells, but no interstitial inflammation. Because the patient had no jaundice-associated confounding factor such as sepsis, heart failure or hepatorenal syndrome that could explain his kidney failure, the authors suggested that bilirubin *per se* should be seen as a cause of acute tubular necrosis. van Slambrouck *et al.* [15] studied 41 autopsies and 3 renal biopsies in 44 jaundiced patients with acute kidney injury. Bile casts were observed 24 times, with involvement of distal nephron segments in 18 mild cases and extension to proximal tubules in 6 more severe cases and they proposed the term bile cast nephropathy. Griffin *et al.* [16] reported a 49-year-old man with progressive obstructive jaundice secondary to PSC who developed acute anuric renal failure requiring prolonged haemodialysis. Renal biopsy showed evidence of tubular epithelial toxicity, pigmented casts, interstitial fibrosis and ischaemic glomerular changes. After orthotopic liver transplantation, there was an immediate urine output recovery, followed by gradual improvement in renal function to a serum creatinine nadir of 210 $\mu\text{mol/L}$. In the present case, liver transplantation also permitted correction of dRTA biological abnormalities. Since kidney biopsy was not performed, whether interstitial inflammation or bile granules in the cytoplasm of distal tubular epithelial cells participated in dRTA cannot be confirmed.

In conclusion, to the best of our knowledge, this case report is the first description of type I dRTA associated with PSC. It illustrates the putative immunological as well as toxic bilirubin-associated mechanisms that may link both entities and reminds us that distal tubular renal function should be carefully assessed in PSC patients with acid-base or electrolyte disorders.

Conflict of interest statement

None declared.

References

1. Soriano JR. Renal tubular acidosis: the clinical entity. *J Am Soc Nephrol* 2002; 13: 2160–2170
2. Haque SK, Ariceta G, Batlle D. Proximal renal tubular acidosis: a not so rare disorder of multiple etiologies. *Nephrol Dial Transplant* 2012; 27: 4273–4287
3. Wrong O, Bruce LJ, Unwin RJ *et al.* Band 3 mutations, distal renal tubular acidosis, and Southeast Asian ovalocytosis. *Kidney Int* 2002; 62: 10–19
4. Li SL, Liou LB, Fang JT *et al.* Symptomatic renal tubular acidosis (RTA) in patients with systemic lupus erythematosus: an analysis of six cases with new association of type 4 RTA. *Rheumatology* 2005; 44: 1176–1180
5. Shioji R, Furuyama T, Onodera S *et al.* Sjögren's syndrome and renal tubular acidosis. *Am J Med* 1970; 48: 456–463
6. Komatsuda A, Wakui H, Ohtani H *et al.* Tubulointerstitial nephritis and renal tubular acidosis of different types are rare but important complications of primary biliary cirrhosis. *Nephrol Dial Transplant* 2010; 25: 3575–3579
7. Halperin ML, Goldstein MB, Haig A *et al.* Studies on the pathogenesis of type I (distal) renal tubular acidosis as revealed by the urinary PCO₂ tensions. *J Clin Invest* 1974; 53: 669–677
8. Batlle D, Grupp M, Gaviria M *et al.* Distal renal tubular acidosis with intact capacity to lower urinary pH. *Am J Med* 1982; 72: 751–758
9. Batlle DC, von Riethe A, Schlueter W. Urinary sodium in the evaluation of hyperchloremic metabolic acidosis. *N Engl J Med* 1987; 316: 140–144
10. Takemoto F, Hoshino J, Sawa N *et al.* Autoantibodies against carbonic anhydrase II are increased in renal tubular acidosis associated with Sjögren syndrome. *Am J Med* 2005; 118: 181–184
11. DeFranco PE, Haragsim L, Schmitz PG *et al.* Absence of vacuolar H(+)-ATPase pump in the collecting duct of a patient with hypokalemic distal renal tubular acidosis and Sjögren's syndrome. *J Am Soc Nephrol* 1995; 6: 295–301
12. Van den Wildenberg MJ, Hoorn EJ, Mohebbi N *et al.* Distal renal tubular acidosis with multiorgan autoimmunity: a case report. *Am J Kidney Dis* 2015; 65: 607–610
13. Aron JH, Bowls CL. The immunobiology of primary sclerosing cholangitis. *Semin Immunopathol* 2009; 31: 383–397
14. Rafat C, Burbach M, Brochériou I *et al.* Bilirubin-associated acute tubular necrosis in a kidney transplant recipient. *Am J Kidney Dis* 2013; 61: 782–785
15. Van Slambrouck CM, Salem F, Meehan SM *et al.* Bile cast nephropathy is a common pathologic finding for kidney injury associated with severe liver dysfunction. *Kidney Int* 2013; 84: 192–197
16. Griffin M, Grande J, Wiesner R *et al.* Prolonged anuria complicating primary sclerosing cholangitis: successful outcome following orthotopic liver transplantation. *Am J Kidney Dis* 1998; 31: 360–363